

## Case Report

# An Unusual Presentation of Microscopic Polyangiitis as Massive Haemoptysis

Ashok Kumar Singh, Shikha Sachan, Aditya N. Shukla and Anjali Tiwari

Department of Pulmonary and Critical Care Medicine, Regency Hospital, Kanpur (Uttar Pradesh), India



This article is available on [www.vpci.org.in](http://www.vpci.org.in)

## ARTICLE INFO

Received: April 7, 2020

Accepted after revision: October 20, 2020

*Indian J Chest Dis Allied Sci* 2021;63:105-107

## KEY WORDS

Anti-neutrophil cytoplasmic antibodies, Microscopic polyangiitis, Thick-walled cavitation, Rapidly progressive necrotising glomerulonephritis.

## ABBREVIATIONS USED IN THIS ARTICLE

MPA = Microscopic polyangiitis

ANCA = Anti-Neutrophil Cytoplasmic Antibodies

TB = Tuberculosis

CT = Computed Tomography

PaO<sub>2</sub> = Partial Pressure of Oxygen

PaCO<sub>2</sub> = Partial Pressure of Arterial Carbon Dioxide

BAL = Bronchoalveolar Lavage

AFB = Acid-fast bacilli

MPO = Myeloperoxidase

## Abstract

Microscopic polyangiitis (MPA) is anti-neutrophil cytoplasmic antibodies (ANCA)-related vasculitis affecting mainly small vessels of lung and kidney. MPA has a varied presentation with a wide variety of multi-systemic symptoms. If this syndrome is not recognised early; it can lead to a lethal outcome. It may mimic tuberculosis (TB) that may lead to problems in the early diagnosis in resource-limited countries, like India, where TB is endemic. We report a case of a female patient who reported to us with massive haemoptysis due to unilateral thick-walled cavitation in the upper lobe, mimicking TB but eventually turned out to be a case of MPA.

## Introduction

Microscopic polyangiitis (MPA) is one of the systemic necrotising vasculitis which commonly affects kidneys, lung, nerves, skin, and joints. It is characterised histologically by the involvement of small vessels and the absence of granulomas.<sup>1</sup> Pulmonary involvement is seen in 22% of the patients and mainly characterised with ground-glass attenuation, consolidation, thickening of bronchovascular bundles and honey-combing on computerised tomography.<sup>2</sup> There are various respiratory presentation of MPA, like diffuse alveolar haemorrhage leading to hypoxic respiratory failure, mild haemoptysis and non-resolving pneumonia. We report a patient with rare pattern of pulmonary involvement presenting with massive haemoptysis and a unilateral thick-walled cavitation on computed tomography (CT) mimicking post primary tuberculosis (TB).

## Case Report

A 70-year old female patient, a known case of diabetes mellitus and hypertension, was admitted to our hospital with complaints of fever, anorexia, and cough and with joint pain for three weeks. Clinical examination, biochemical and microbiological investigations were within normal limits. Chest radiograph (postero-anterior view) revealed

**Corresponding author:** Dr Ashok Kumar Singh, Consultant, Pulmonary and Critical Care Medicine, Regency Hospital, Kanpur-208 005 (Uttar Pradesh), India; E-mail: [dr\\_ashok\\_rhl@yahoo.com](mailto:dr_ashok_rhl@yahoo.com)

bilateral diffuse opacities in both the lower lung fields. Computed tomography of the chest revealed bilateral ground-glass opacities, suggestive of diffuse alveolar involvement. The differential diagnosis included viral pneumonia or diffuse alveolar haemorrhage. Patient responded to conservative symptomatic management and was discharged. The patient was lost to follow-up for three months.

After three months, she was again admitted with a two-day history of high grade fever, cough with shortness of breath and massive haemoptysis for few hours. Her vital signs were: respiratory rate 24 per minute, blood pressure 100/64 mmHg, pulse rate-?. Examination of the patient revealed bilateral fine crepitations. Laboratory investigations were as follows: white cell count 14000/mm<sup>3</sup> (polymorphs 88%, lymphocytes 10%, eosinophils 2%), haemoglobin 9.8 g/dL%, sodium 136 mEq/L% potassium 4.7 mEq/L, serum creatinine 3.3 mg/dL There was no eosinophilia in the peripheral blood.

Arterial blood gas analysis at room air was partial pressure of arterial oxygen (PaO<sub>2</sub>) 72.4mmHg, partial pressure of arterial carbon dioxide (PaCO<sub>2</sub>) 32mmHg, pH 7.21. Bedside chest radiograph (postero-anterior view) revealed right-sided, thick-walled cavitation and scattered ground-glass opacities (Figure 1). Non-contrast CT of the chest showed right upper lobe thick-walled cavitation (Figure 2A, B). Fiberoptic bronchoscopy revealed edematous and haemorrhagic mucosa on right side. The bronchoalveolar lavage (BAL) was blood stained and was negative for acid-fast bacilli (AFB), fungal smear, malignant cells and bacterial culture and also negative on cartridge-based nucleic acid amplification test (CBNAAT) (Gene-Xpert®).

During hospitalization, her serum creatinine levels increased progressively over next five days. In spot urine analysis, there was proteinuria and haematuria. Renal ultrasound revealed bilaterally grade 1 medical renal disease. Transcutaneous renal biopsy was performed which revealed diffuse glomerulonephritis associated with small vessel vasculitis. There was no evidence of granulomatous inflammation and eosinophilic infiltration. While antiglomerular basement membrane antibody was negative, p-ANCA specific to myeloperoxidase (MPO) was positive in very high titer. Based on these findings, a diagnosis of microscopic polyangiitis was made.

The patient was managed with combined immunosuppressive treatment for remission induction with methylprednisolone (1 mg/kg/day) and pulse cyclophosphamide (1 g). The patient had a fulminate hospital course with worsening renal function and anuria. She was managed with haemodialysis. However,

in third week of hospitalisation, she had an episode of massive haemoptysis and had a cardiopulmonary arrest. In spite of aggressive resuscitation including invasive ventilation with single lung intubation; the patient died after few days.

## Discussion

Microscopic polyangiitis is the most common ANCA-associated small vessel vasculitis and is characterised by the presence of ANCA and few immune deposits in the involved vessels. The most common differential diagnosis of MPA is granulomatosis with polyangiitis. Rapidly progressive glomerulonephritis is one of its major characteristic features at presentation. Other clinical symptoms such as alveolar haemorrhage, cutaneous, musculoskeletal, gastrointestinal system, neurological and ear-nose-throat involvement may also be found; but occur less frequently.<sup>3</sup>

Our patient was admitted to hospital with massive haemoptysis, fever and respiratory distress suggesting some acute infective process. She also had an episode

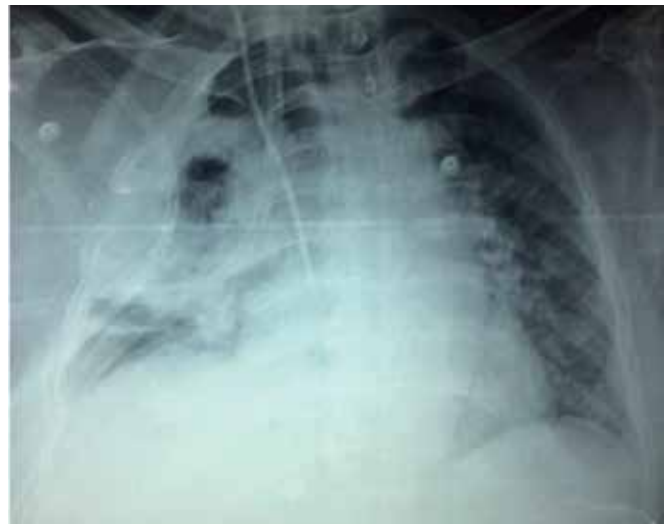

Figure 1. Bedside chest radiograph (postero-anterior view) revealed right-sided thick-walled cavitation and ground-glass opacity in both the lung fields.

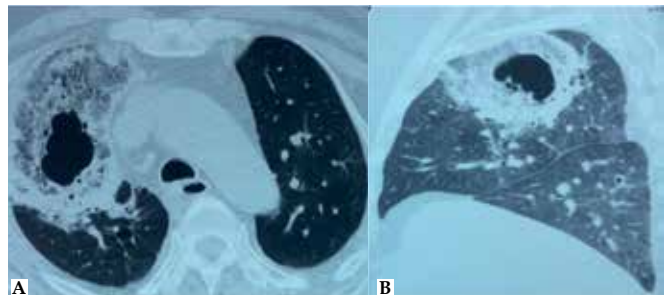


Figure 2 (A) coronal section, (B) sagittal section. Non-contrast computed tomography of the chest showing right upper lobe thick-walled cavitation.

of diffuse alveolar haemorrhage three month back. In various case series alveolar haemorrhage was reported in 12% to 79% of the patients with MPA and is associated with high morbidity and mortality. Chest radiograph features observed in MPA include patchy, bilateral airspace opacities and or a nonresolving pneumonia. Rarely, normal chest radiograph also can be seen in MPA patients.<sup>4</sup>

Computed tomography of chest finding in MPA patients are also non-specific. Ando *et al* reviewed the CT findings in 51 MPA patients with pulmonary involvement in the form of ground-glass attenuation, consolidation, honeycombing, nodules larger, bronchiectasis, pleural effusion and enlarged mediastinal lymph nodes.<sup>5</sup> In the present case, first CT of chest showed ground-glass attenuations; which later evolved into unilateral thick-walled cavitation in the right upper lobe mimicking tuberculosis.

For confirming the diagnosis of MPA, serum p-ANCA is an important serological marker. The p-ANCA pattern with antibodies to MPO is most closely associated with MPA. Lauque *et al*<sup>2</sup> revealed that p-ANCA antibodies were present in 93% of MPA patients. Presence of c-ANCA was reported in only 8% to 10% of the patients.<sup>2</sup> In our patient, p-ANCA with anti-MPO activity was positive. Also, antiglomerular basement membrane antibody was negative. Lung biopsy is not usually advised in the setting if serological markers are suggestive of MPA diagnosis.<sup>6</sup> Renal biopsy is a valuable tool that yields a rapid diagnosis of crescentic glomerulonephritis and allows a rapid initiation of treatment, even in patients with microscopic haematuria without renal failure. In our case, renal

biopsy revealed crescentic glomerulonephritis without granulomatous inflammation and immune deposits.

In conclusion, MPA is an autoimmune vasculitis affecting multiple organs. Sometime pulmonary involvement can mimic common disease, like pulmonary tuberculosis. In our case, there was significant pulmonary involvement but presentation was atypical in the form of diffuse alveolar haemorrhage in early stage and thick walled cavitation leading to massive haemoptysis in later stage. A high index of suspicion is needed to appropriately diagnose these cases.

## References

1. Collins EC, Quismorio FP. Pulmonary involvement in microscopic polyangiitis. *Curr Opin Pulm Med* 2005;11:447-51.
2. Lauque D, Cadranet J, Lazor R, Pourrat J, Ronco P, Guillevin L, *et al*. Microscopic polyangiitis with alveolar hemorrhage: a study of 29 cases and review of the literature. *Medicine (Baltimore)* 2000;79:222-33.
3. Eschun GM, Mink SN, Sharma S. Pulmonary interstitial fibrosis as a presenting manifestation in perinuclear antineutrophilic cytoplasmic antibody microscopic polyangiitis. *Chest* 2003;123:297-301.
4. Savage C, Winearls C, Evans D. Microscopic polyarteritis: presentation, pathology and prognosis. *Q J Med* 1985;56:467-83.
5. Ando Y, Okada F, Matsumoto S, Hiromu M. Thoracic manifestation of myeloperoxidase-antineutrophil cytoplasmic antibody (MPO-ANCA)-related disease: CT findings in 51 patients. *J Comput Assist Tomogr* 2004;28:710-6.
6. Burns A. Pulmonary vasculitis. *Thorax* 1998;53:220-7.